

CANTHO-PLASTY 8

AS A

REMEDY

IN

CERTAIN DISEASES OF THE EYE

BY C. R. AGNEW, M. D.,

Clinical Professor of Diseases of the Eye and Ear, College of Physicians and
Surgeons, New York; Surgeon to the Manhattan Eye and
Ear Hospital, etc.



NEW YORK:

G. P. PUTNAM'S SONS,

FOURTH AVE. AND TWENTY-THIRD ST.

1875.

CANTHO-PLASTY

AS A

REMEDY

IN

CERTAIN DISEASES OF THE EYE

BY C. R. AGNEW, M. D.,

Clinical Professor of Diseases of the Eye and Ear, College of Physicians and Surgeons, New York; Surgeon to the Manhattan Eye and Ear Hospital, etc.



NEW YORK:
G. P. PUTNAM'S SONS,

FOURTH AVE. AND TWENTY-THIRD ST.

1875.

CANTHO-PLASTY

AS A

REMEDY IN CERTAIN DISEASES OF THE EYE.

By C. R. AGNEW, M.D., New York, Clinical Professor of Diseases of the Eye and Ear, College of Physicians and Surgeons, New York; Surgeon to the Manhattan Eye and Ear Hospital, etc.

The therapeutical value of the operation of Cantho-plasty is not as highly appreciated as it should be. The purpose of this brief paper is to show its adaptation as a means in the treatment of certain forms of corneal and conjunctival diseases, and thus to obtain for it a more general trial by the profession at large.

All whom I address must have had cases of phlyctenular, or so-called strumous, ophthalmia, in which the recurrence of small vesicles, pustules, or ulcers in the limbus of the cornea, or upon its general surface, accompanied by more or less intense and persistent photophobia, resisted every form of local and general therapeutic measure.

Frequently these intractable forms of the disease occur in children, and producing more or less dread of light, lead to the sufferer being confined to the domicile, and in other ways subjected to a most unhygienic regimen, and the debilitating influence of so-called antiphlogistic treatment. Any malady which deprives a growing child of its natural, playful exercises, and shuts it up in the poisonous atmosphere of an imperfectly lighted and ventilated, or overheated domicile, is eminently worthy of our earnest and thoughtful attention.

The more intractable forms of these diseases occur in children who may have inherited feeble constitutions. In many instances, however, they occur in those who have been born without any special constitutional defect, but who have had their digestive and other blood-making organs injured by a promiscuous dietary, and too little out-of-door life. The practice, common in every walk of

life, of giving the diet of the family table to a young child so soon as it can stretch out its hands to gratify its natural gluttonous propensities, is here seen to produce one of its many evil results. Such remarks may seem to some to be trite, but they will not cease to be pertinent so long as the evil at which they are aimed continues to be so wide-spread. If children when weaned were put first upon a milk and then a milk and farinaceous diet, and not allowed to have the full, promiscuous dietary of adult life, we would see a vast improvement in public health and a lower death-rate. We would, moreover, see less of those forms of self-indulgence which spring from the uncontrolled selfishness and gluttony that begin at the nursery table.

We are prepared to urge, then, in every case of phlyctenular or eruptive inflammation of the conjunctiva, that the diet and regimen be placed upon a hygienic basis. We should also prescribe woolen underclothing, with a change of the same for the night, that the winter temperature of the domicile need not be kept above 65° . We should improve the action of the skin by alkaline or saline baths and daily friction. We should insist upon daily out-of-door life, and keep the child, when domiciled, in a well-lighted room, warmed, or at least ventilated, if possible, by an open fire in winter, and its eyes free from eyeshades, bandages, poultices, and sugar of lead washes. When I say well-lighted rooms, I do not mean those middle or inside rooms in which so many people spend so much time, or in which they incarcerate their children, but outside rooms that are penetrated and purified by direct sunlight. A child should never be allowed, sick or well, to play long or sleep in a room that is not above the ground level and daily pervaded by direct sunlight. People who value the lives of their children should select their homes with these things in view.

As regards local treatment in these cases of phlyctenular disease, solutions of sulphate of atropia, adapted in strength to the age of the subject, will be found of great value. The strength of such solutions may vary from a quarter of a grain to a grain to the ounce of distilled water, and the frequency of instillation, from once a day to four or five times a day, according to the intensity of the symptoms. Two or three times a day the eyes should be bathed with a drachm to the pint solution of common salt, epsom salts, or carbonate of soda, at any agreeable temperature. In many cases the use of levigated calomel by insufflation two or three times a week, will do good. The latter is valuable especially in cases in which

the ulceration is very superficial, or is of an aphthous character, and shows a tendency to hold on its surface an unclean, or yellowish-looking, pasty crust of partially disintegrated epithelium.

Leeches and blisters behind the ear are not indicated, but the photophobia may be sometimes relieved by painting the supra-orbital regions with tincture of iodine, or giving fluid extract of conium to the point of producing its physiological effects. Eye drops of nitrate of silver are not indicated, and the use of solutions of acetate of lead are most objectionable, as they endanger the eye by often producing indelible deposits in corneal ulcers.

Internally, in addition to a simple dietary, we may employ cod-liver oil, iron, arsenic, and preparations of lime and soda, and an occasional laxative of rhubarb, senna, or a mild saline, such as a small dose of epsom salts given in hot water, and made palatable by the addition of fruit syrups, or otherwise.

A change of atmosphere, such as that from the interior of the country to the coast, or the reverse, or from a low, sour soil to that of a higher and better drained level, or even from a basement room to a higher level in the domicile, will often prove remedial. But failing these means we have remaining the surgical procedure, to describe which is the principal object of my contribution.

The eyelids owe their shape and close contact with the surface of the eyeballs largely to the layer of somewhat firm and condensed connective tissue which holds the tarsal cartilages in place, is spread out beneath the orbicular muscle, and external to the palpebral conjunctiva, and loses itself around the edge of the orbit by becoming incorporated with the surface of the periosteum. Near the outer canthus this layer of tissue is re-inforced, both above and below the horizontal line of the palpebral slit, to form the external canthal ligaments, and serves to anchor the edges of the eyelids to the temporal edge of the orbit.

In persistent, or frequently recurring phlyctenular disease, the orbicular muscle becomes preternaturally active, being engaged either in maintaining the diseased eye in a closed state, or in a more or less active winking under the influence of the photophobia. At first this activity of the orbicular muscle, caused by the phlyctenular disease and the dread of light, seems to be one of the curative efforts of nature. After the disease has lasted some weeks, however, and resisted all curative means, or having been apparently cured, has recurred, and that too in the face of the best care, the morbid and unregulated activity of the orbicular muscle

oftentimes becomes the grand cause of the perpetuation of the malady.

The eye can no longer have due exposure to air and light by reason of the almost incessant contraction of the muscle, and some surgical interference is demanded. The condition in some of its manifestations of reflex action is not unlike that which we see in fissure of the anus, or irritable ulcer of the lower rectum, where the surgeon is forced to cut or tear the sphincter ani, that the fissure or ulcer may have a chance to heal unvexed by the incessant strain of an irritated sphincter. It has some points of resemblance to those forms of reflex urethral disease to which Professor F. N. Otis has called the attention of the profession. It belongs to the large family of neuroses of sensibility upon which much light is beginning to converge as we get more knowledge of the anatomy and physiology of the vaso-motor system and reflex nerve action.

We come now to describe the method we employ in doing the operation. An anæsthetic should be given, except in the cases of those rare adults who do not dread bodily pain. The subject lying on his back, the external commissure of the eyelids should be split to the bottom of the conjunctival *cul-de-sac*, through skin,

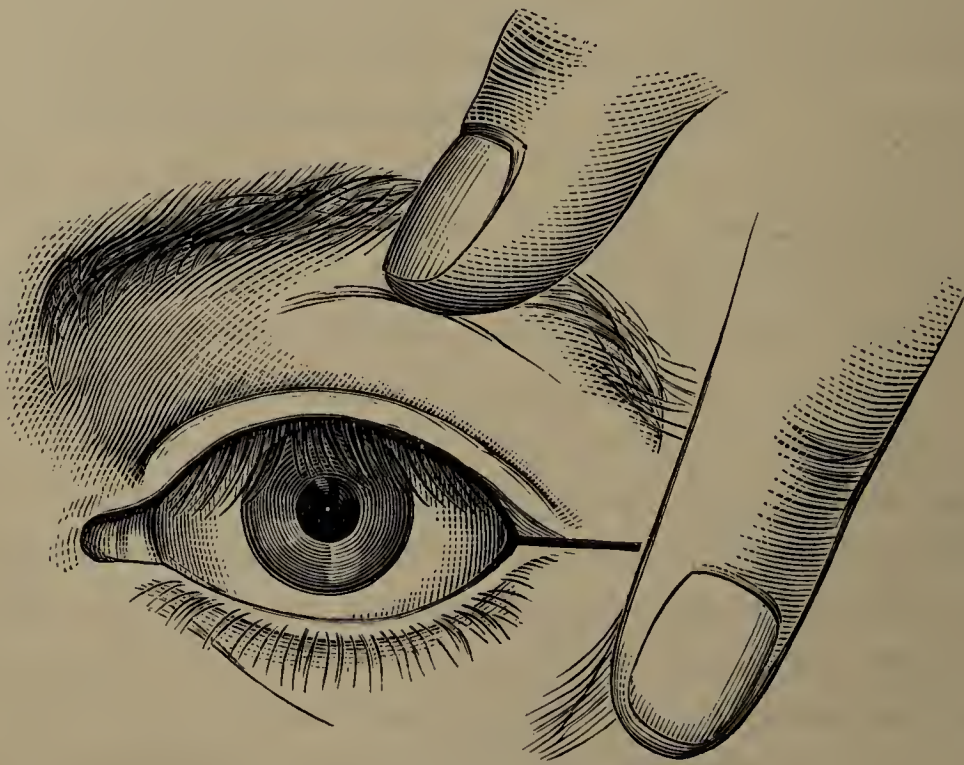


Fig. 1.

orbicular muscle, canthal ligament, and conjunctiva. This is best done with a pair of strong, sharp scissors, that will cut to the points. The length of the cut will vary from a half to five-eighths

of an inch, depending upon the depth of the *cul-de-sac*. Its direction should be accurately horizontal, or perpendicular to the external commissure, to insure which the operator should open the eyelids with two fingers of his left hand, before introducing the scissors. In introducing the scissors to make the cut, one blade should pass behind the commissure and one blade in front. The direction of the cut is well shown in figure No. 1. There will be some bleeding, perhaps an arterial spurting, which a little time will suffice to stop without the use of any ligature. After the incision, the palpebral slit will be found to be elongated, as is shown in figure No. 2, where the small black vertical lines on the upper and lower eyelids indicate the extent of the original commissure.




Fig. 2.

The next step is for the operator to take the upper eyelid between his thumb and forefinger, and draw it a little in an upward direction and towards the nose, until he feels the external canthal ligament upon the stretch. When this is felt he should introduce the blades of a medium-size pair of scissors into the wound, and nick the stretched edge of said ligament in the vicinity of the orbital border. It will be necessary to remember that the edge of the canthal ligament to be cut is that which extends from the end of the tarsal cartilage of the upper eyelid to the temporal border of the orbit, and that the direction of the snipping with the scissors should be at right angles to the first incision through the commissure, and at a distance of about two lines from the place where the ligament spreads out on the temporal border of the orbit. If the upper eyelid be firmly held as directed during this step of the procedure, and so drawn towards the nose as to keep the ligament on the stretch, the surgeon will be easily able to so place the points of his scissors as that one blade will slip into the space above the ligament, and between it and the skin, while the other will pass

beneath the ligament into the space between the latter and the conjunctiva. When the directions are thus thoughtfully followed there will be an appreciable yielding of the lid to the traction the moment that the edge of the ligament is nicked, a feeling that all will recognize who have ever divided a tense tendon.

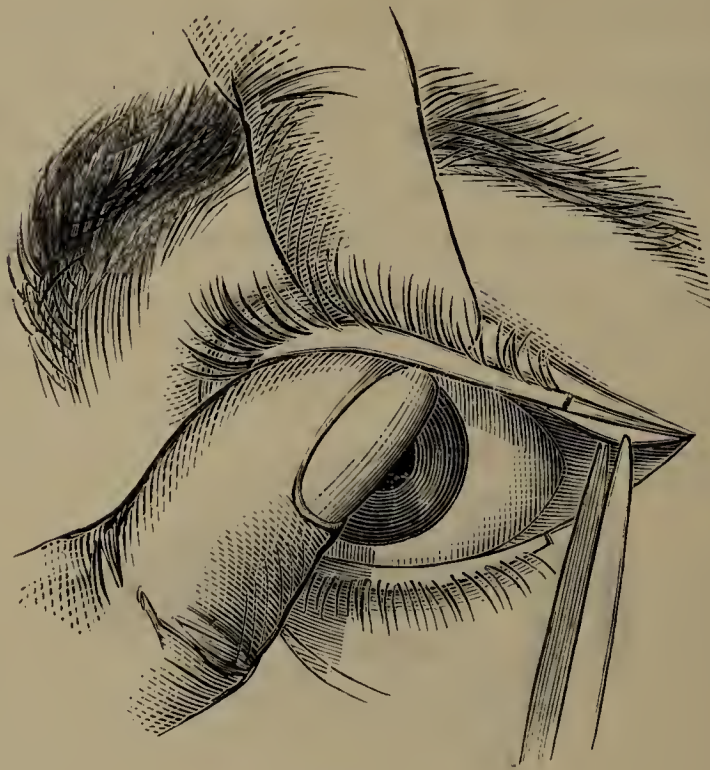


Fig. 3.

Fig. 3 shows the eyelid as held, and the blades of the scissors in position to snip the stretched tarsal ligament.

The tarsal ligament in the *lower* lid should *not* be cut. Such an incision is unnecessary, and might do great harm by producing a relaxed and everted state of the lower eyelid, a danger never incurred by operating upon the upper eyelid.

The next step is to apply three or four fine sutures so as to stitch the cut conjunctiva neatly to the cut skin all around the enlarged or new commissure, excluding from the sutures the cut ligament. The following small diagram will show the shape of the wound.

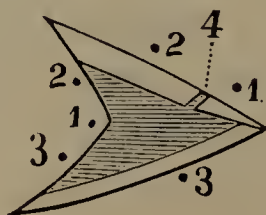


Figure 4, in it, shows where the tarsal ligament has been snipped, while 1, 1, 2, 2, and 3, 3, show where three sutures are to be placed to draw conjunctiva to skin around enlarged commissure.

Figure 5 shows the new commissure, after the sutures shall have been tied and the operation completed.

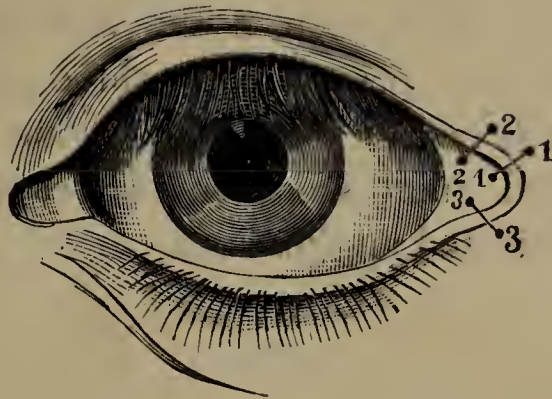


Fig. 5.

It will now be found that the palpebral slit has been lengthened, and that the upper eyelid does not grasp the eyeball so firmly as before.

The maintenance of the new commissure should be aided by careful cleansing of the wound from time to time, so as to prevent the formation of any scabs that would tend by their contraction to draw it together. This result should also be favored by the application of simple cerate. At the end of forty-eight hours the sutures may be removed, and the angle or commissure gently opened by stretching, should there be any tendency to bridging over. In the course of a few weeks there will be found little or no physical trace of the operation, except a somewhat rounded commissure and a lessening of the firm coaptation between the eyelid and the eyeball. This change occasions no drooping of the lid, and is chiefly appreciated by the patient, who enjoys a greater immunity from recurrent phlyctenular disease, or from any affection of the cornea that had been produced or kept up by a contracted palpebral slit, or roughness of the palpebral conjunctiva.

The application of this procedure is wider than might at first seem possible, as the following table of one hundred and ninety-one cases will serve to show.

In no cases is its beneficial effect more striking than in recurring or obstinate phlyctenular disease, unless it may be in those in which palpebral roughness, as from granulations, threatens the integrity of the cornea by inducing pannus or ulceration. In cases of violent purulent inflammation, a thorough division of the external commissure, without the use of sutures, may, by the bleeding which it causes and the diminished pressure from the swollen lids, greatly lessen the risk of loss of the affected eye.

In these latter cases the swelling soon makes the eyelids so immovable as to prevent thorough removal of the pus from the eyeball, and proper application of remedies to subdue the inflammatory action. In such cases, then, if the external commissure be freely split down to the orbital edge, three salutary results will ensue; first, there will be free bleeding; second, there will be lessened pressure; third, increased ease in cleansing the inflamed eye and making medicated applications.

TABLE.

Granular Lids.....	22
" " with Pannus.....	48
" " Ulcerative Keratitis.....	15
Pannus.....	14
Keratitis.....	17
" Phlyctenular and Conjunctivitis.....	41
" Parenchymatous.....	4
" Ulcerative.....	4
Entropion, trichiasis.....	12
Ectropion.....	1
Conjunctivitis, chronic.....	2
" " purulent.....	6
" " blepharospasm.....	2
Blepharo-facial spasm.....	1
Panophthalmitis.....	2
	191

